



## Morphometric assessment of microvessel density in astrocytomas : a tertiary care center study

**Corresponding Author:** Dr. Sonia Singh , Assistant Professor

Dr. Radha krishnan Govt. Medical College, Hamirpur, Himachal Pradesh ,Phone numbers: 9416529299

Dr Rinky langan, deptt of Pathology, Oncquest Lab

Dr Sonia Singh, deptt of Pathology, Dr.RKGMCC, Hamirpur

E-mail address : dr.soniagulia@gmail.com

Article Received 14-04-2020 , Accepted 14-06-2020 , Published 01-07-2020

### **Abstract**

**Aims:** To evaluate and compare microvessel density morphometrically using endoglin (CD105) and CD34, a pan-endothelial marker in different histological grades of astrocytoma

**Settings and Design:** tertiary care centre , original artical

**Methods and Material:** In 61 cases of astrocytoma, the expression of CD105 and CD34 antibody was morphometrically assessed and mean microvessel density (per mm<sup>2</sup>), total microvessel area (expressed as μm<sup>2</sup> per mm<sup>2</sup> and as percentage) were calculated and compared in different grades. Ten cases of normal brain tissue retrieved from the archives of department of pathology that had been submitted for postmortem examination were used as control.

**Statistical analysis used:** Mean values of the parameters studied were analyzed using SPSS (Statistical Package for Social Studies) statistical program version 18. In all tests, p values less than 0.05 were regarded as significant. For comparison between different groups for each antibody, Kruskal-Wallis test was applied and for comparison between two antibodies among all groups, Mann-Whitney U test was used.

**Results:** Mean microvessel density (MVD)-CD34 in grade I – IV astrocytoma was 14.5±5.3, 24.1±5.4, 61±8.7 and 89.4±10.7 respectively while MVD-CD105 was 9.40±0.41, 13.97±0.68, 35.72±0.51 and 49.66±1.17 respectively. The total microvessel area (TVA) in grade I – IV astrocytoma using CD34 antibody was 9908±1399.21, 13827±2798.82, 47235±4094.19 and 64840±5656.58 μm<sup>2</sup> per mm<sup>2</sup> (r=0.95; p<0.05). The total microvessel area (TVA) was 4865.86±40.91, 6721.16±365.33,

22516.14±185.51 and 31458.9±131.45  $\mu\text{m}^2$  per  $\text{mm}^2$  in grade I – IV astrocytoma respectively on using CD105 antibody.

**Conclusions:** Tumor angiogenesis is an integral component in the progression of low grade astrocytoma to glioblastoma multiforme. TVA and MVD increases with increasing grade of the astrocytomas.

**Key-words:** Microvessel Density, Angiogenesis, Astrocytom

**Key message:** The assessment of intra-tumor microvessel density can act as a measure of angiogenic activity and an increase in angiogenesis is a hallmark of malignant transformation.

## INTRODUCTION

Gliomas, the most common primary tumors of the brain, include neoplasms revealing astrocytic, oligodendroglial or ependymal differentiation. Amongst them, astrocytomas are the most common which may present as a circumscribed lesion (e.g. pilocytic astrocytoma) or as a diffusely infiltrating neoplasm. The latter include fibrillary astrocytoma, anaplastic astrocytoma and glioblastoma multiforme (GBM) which are divided and graded on the basis of four histologic criteria i.e. nuclear atypia, mitotic activity, endothelial proliferation and the presence of necrosis. The morphological hallmark of Glioblastoma multiforme is the presence of geographic necrosis lined by palisading tumor cells and a complex form of microvascular proliferation (MVP) forming glomeruloid configurations.<sup>[1]</sup>

Angiogenesis is the process of formation of new vasculature and is the most crucial element in the survival and proliferation of neoplastic cells for it not only provides oxygen and nutrients to

the proliferating cells but also increases its probability to metastasize. Various factors, which act on different stages, are responsible for angiogenesis in the tumors of central nervous system leading to formation of network of new vessels. These factors include basic fibroblast growth factor (bFGF), transforming growth factor –  $\beta$ 1 (TGF- $\beta$ 1), epidermal growth factor (EGF), platelet derived growth factor (PDGF) and vascular endothelial growth factor (VEGF). VEGF is an endothelial cell mitogen playing a pivotal role in formation of new blood vessels during embryogenesis.<sup>[2]</sup> It is one of the major angiogenic factors implicated in the progression of astrocytomas. Low oxygen tension in the rapidly dividing brain tumor cells induces the expression of hypoxia-inducible factor 1 (Hif-1), a transcription factor that up regulates the expression of many angiogenesis related genes including VEGF gene. This is validated from the fact that cells adjacent to the areas of palisading necrosis show increased expression of VEGF.<sup>[3]</sup> Angiopoietins (Ang-1 and Ang-2), unlike VEGF, act on late stages of angiogenesis and are responsible for vascular remodeling and maturation.<sup>[2]</sup> The markers that are often used to highlight endothelial cells belong to two major categories: pan-endothelial cell antibodies and the other which bind specifically to the activated or proliferating endothelium associated with neoangiogenesis. The pan-endothelial markers like CD31, CD34 and VEGF stain the proliferating and the trapped normal vessels with equal intensity. However, the markers specific to the proliferating vessels like endoglin (CD105) show weak or no positivity towards mature, pre-existing vessels while demonstrating only the proliferating vessels.<sup>[4]</sup>

Endoglin is a 180 kDa transmembrane protein which is predominantly expressed on tumor

associated endothelial cells (ECs) and functions as a receptor for transforming growth factor –  $\beta 1$  (TGF- $\beta 1$ ).<sup>[5]</sup> Microvessel density (MVD) calculated by using endoglin (CD105) when compared with that of pan-endothelial markers have been found to be better predictor of prognosis in many tumors like breast carcinomas, gliomas, non small cell lung cancer.<sup>[6-8]</sup>

The aim of the present study was to compare CD34, a pan-endothelial marker with endoglin (CD105) in different histological grades of astrocytoma. The parameters that were used to assess angiogenesis were MVD, total microvessel area (TVA) expressed as  $\mu\text{m}^2$  per  $\text{mm}^2$  of the tumor and percentage area occupied by microvessels. These parameters were calculated with the help of computer assisted image analysis.

## **MATERIAL AND METHODS**

Sixty-one cases of astrocytic tumors, submitted in the Department of Pathology, Pt. B.D. Sharma PGIMS, Rohtak for histopathological examination, were processed by routine histological techniques. Histopathological diagnosis was established and each case was graded as per WHO classification of Brain Tumours, 2007. Ten cases of normal brain tissue were retrieved from the archives of the Department of Pathology submitted for postmortem examination. Normal brain tissue and cases of Astrocytic Tumors were divided into five groups; *Group I*: normal brain tissue, *Group II*: Grade I Astrocytoma, *Group III*: Grade II Astrocytoma, *Group IV*: Grade III Astrocytoma, *Group V*: Grade IV Astrocytoma.

### **Immuno histochemistry and Morphometry**

For endothelial cell visualization, representative sections of each sample were subjected to staining with CD34 (clone QBEnd 10, dilution 1:50, DAKO) and CD105 (Endoglin, clone SN6h, dilution 1:10, DAKO). The sections were scanned at low magnification and area with the highest density of capillaries and small venules or the 'neovascular hot spot' was identified according to the method described by Weidner et al,<sup>[9]</sup> microvessel density (MVD) was assessed at both 200x and 400x field.

The quantitative morphometric studies were done by image analysis. Images provided by the charged device video camera coupled with Olympus BX51 microscope at 200x and 400x magnification were stored on computer through a digital frame grabber and processing was done by image analysis software Image Pro Plus Version 6.3.

The parameters studied were i) Microvessel Density (MVD): all vascular structures and cells stained with anti-CD34 and anti-CD105 antibodies respectively were analysed in each microscopic field of 200x and 400x and highlighted by outlining their digitalized images on monitor screen. Three microscopic fields were examined by two observers independently at both 200x and 400x and a mean value was calculated for both the antibodies. MVD was expressed as number of vessels per  $\text{mm}^3$  of the tumor. (ii) Total vascular area (TVA): total area of stained vessels was measured for both the antibody and expressed as percentage area of the tumor occupied by positively stained vascular structures.

### **Statistical analysis:**

Mean values of the parameters studied were analyzed using SPSS (Statistical Package for Social Studies) statistical program version 18. In

all tests, p values less than 0.05 were regarded as significant. For comparison between different groups for each antibody, Kruskal-Wallis test was applied and for comparison between two antibodies among all groups, Mann-Whitney U test was used.

## RESULTS

Of total 61 cases, the distribution according to the progressive grades of astrocytoma is as follows: 11 cases of pilocytic astrocytoma (18% of total cases), 18 of Diffuse Astrocytoma (29%), 11 of Anaplastic Astrocytoma (18%) and 21 cases of Glioblastoma Multiforme (GBM, 35% of total cases). The mean age of patients with grade I, grade II, grade III and grade IV astrocytoma was 28.5, 33.8, 34.7 and 51.7 years. The majority of the cases with grade I and grade II astrocytoma belonged to 21-30 years age group while the age group of majority of grade IV astrocytoma cases was 51-60 years. The incidence of all grades of astrocytoma was found to be more in males as compared to females with Male : Female of 3.7:1. Frontal lobe was the preferred site with 63% of grade I, 55.5% of grade II and 82% of grade III cases and 42% of grade IV cases occurred in frontal lobe, forming 57.5% of the total cases.

The microvessel density using CD34 and CD105 antibody in the control group was found to be

$3.9 \pm 1.2$  and  $1.95 \pm 0.6$  respectively. The total microvessel area using CD34 and CD105 antibody of the control group was  $1401 \pm 215.28$  and  $629 \pm 222.29 \mu\text{m}^2$  per  $\text{mm}^2$ . The percentage area using both antibodies was  $0.14 \pm 0.02\%$  and  $0.06 \pm 0.02\%$  respectively.

On using CD34 antibody, the mean microvessel density in grade I – IV astrocytoma was  $14.5 \pm 5.3$ ,  $24.1 \pm 5.4$ ,  $61 \pm 8.7$  and  $89.4 \pm 10.7$  respectively (pearson' coefficient,  $r=0.96$ ;  $p<0.05$ ) while the mean MVD-CD105 of grade I – IV astrocytoma was  $9.40 \pm 0.41$ ,  $13.97 \pm 0.68$ ,  $35.72 \pm 0.51$  and  $49.66 \pm 1.17$  respectively ( $r=0.97$ ;  $p<0.05$ ).

The total microvessel area (TVA) in grade I – IV astrocytoma using CD34 antibody was  $9908 \pm 1399.21$ ,  $13827 \pm 2798.82$ ,  $47235 \pm 4094.19$  and  $64840 \pm 5656.58 \mu\text{m}^2$  per  $\text{mm}^2$  ( $r=0.95$ ;  $p<0.05$ ). The percentage area was  $0.99 \pm 0.13\%$ ,  $1.38 \pm 0.27\%$ ,  $4.72 \pm 0.40\%$  and  $6.48 \pm 0.56\%$  respectively ( $r=0.95$ ;  $p<0.05$ ). On using CD105 antibody, the total microvessel area (TVA) was  $4865.86 \pm 40.91$ ,  $6721.16 \pm 365.33$ ,  $22516.14 \pm 185.51$  and  $31458.9 \pm 131.45 \mu\text{m}^2$  per  $\text{mm}^2$  in grade I – IV astrocytoma respectively ( $r=0.96$ ;  $p<0.05$ ). The percentage area calculated was  $0.48 \pm 0.004\%$ ,  $0.67 \pm 0.03\%$ ,  $2.25 \pm 0.02\%$  and  $3.14 \pm 0.01\%$  in respective grades of astrocytoma ( $r=0.96$ ;  $p<0.05$ ). [Table 1]

	Total number of cases (n)	Mean age of patients (years)	MVD - CD34 (per mm <sup>2</sup> )	MVD- CD105 (per mm <sup>2</sup> )	TVA -CD34 (μm <sup>2</sup> per mm <sup>2</sup> )	TVA CD34 (%age)	TVA-CD105 (μm <sup>2</sup> per mm <sup>2</sup> )	TVA CD105 (%age)
Control	10		3.9±1.2	1.95±0.6	1401±215.28	0.14±0.02	629±222.29	0.06±0.02
Pilocytic Astrocytoma	11 (18%)	28.5	14.5±5.3	9.4±0.41	9908±1399.21	0.99±0.13	4865.86±40.91	0.48±0.004
Diffuse Astrocytoma	18 (29%)	33.8	24.1±5.4	13.97±0.68	13827±2798.82	1.38±0.27	6721.16±365.33	0.67±0.03
Anaplastic Astrocytoma	11 (18%)	34.7	61±8.7	35.72±0.51	47235±4094.19	4.72±0.40	22516.14±185.51	2.25±0.02
Glioblastoma Multiforme	21 (35%)	51.7	89.4±10.7	49.66±1.17	64840±5656.58	6.48±0.56	31458.9±131.45	3.14±0.01

Table 1: MVD and TVA, using CD105 and CD34 antibodies in different grades of astrocytoma.

## DISCUSSION

Tumor angiogenesis is an integral component in the progression of low grade astrocytoma to glioblastoma multiforme. The microvascular proliferation characteristic of glioblastoma multiforme results from the increased production of angiogenic factors. This unbalanced angiogenesis leads to the formation of coiled, glomerulus-like capillary loops, hallmark of glioblastoma multiforme.

The assessment of intra-tumor microvessel density, as a measure of angiogenic activity has been studied in many malignant tumors such as prostate, endometrium, colorectal cancer, laryngeal cancers and oligodendroglioma.<sup>[10-14]</sup> Laitakari et al showed that increase in angiogenesis is a hallmark of malignant

transformation and was most prominent in poorly differentiated squamous cell carcinoma in laryngeal cancers.<sup>[13]</sup> Netto et al conducted their study on oligodendroglioma and showed that microvessel counts increased with increase in tumor grades.<sup>[14]</sup>

Several authors have compared the microvessel density using CD105 antibody and CD34 antibody in various neoplastic lesions. Kumar et al used antiCD105 and anti-CD34 antibody to quantify MVD in breast carcinoma and found that the MVD counts using anti-CD105 antibody correlated significantly with overall and disease free survival, whereas no such correlation was seen using pan endothelial marker (CD34). Furthermore, they found that CD105 highlighted specifically the tumor associated vessels while the conventional pan-endothelial

antibody CD34 was an unreliable marker for visualizing them.<sup>[15]</sup>

Yao et al evaluated various clinicopathological parameters of hepatocellular carcinoma with microvessel density and demonstrated that the higher score of MVD-CD105 correlated with both patient's disease-free and overall survival ( $p = 0.002$  and  $p = 0.009$ , respectively), whereas MVD-CD34 correlated with only overall survival ( $p = 0.052$ ) but not with disease-free survival analysis.<sup>[16]</sup> Tanaka et al studied non small cell lung cancer and discovered the prognostic significance of MVD obtained using anti-CD105 antibody which also correlated with the expression of vascular endothelial growth factor.<sup>[8]</sup> Sugita et al noticed that intra-tumor microvessel density as determined by anti-CD105 mab was a reliable prognostic marker in primary central nervous system lymphomas (PCNSLs) when compared with CD34 microvessel density.<sup>[17]</sup>

High grade astrocytomas are regarded as one of the most vascular neoplasms. The detection of specific angiogenic markers involved in the progression of neoplasm would be crucial in planning conventional therapy. Yao et al studied the expression of CD105 in human gliomas and compared it with that of CD34 antibody. They found that CD105-MVD correlated more closely to the pathological grade of gliomas as compared with CD34-MVD and proposed CD105 as a specific and superior marker in quantitation of angiogenesis in glioma.<sup>[18]</sup> Behrem et al compared CD105, CD31 and VEGF in the assessment of angiogenesis in 46 patients of glioblastoma multiforme and evaluated their role in the prognosis and observed that, though, the expression of both CD31 and CD105 was associated with the VEGF expression, CD105

showed stronger correlation with patient's survival.<sup>[19]</sup>

The present study revealed that the degree of angiogenesis correlates with increasing grades of astrocytoma. The MVD, when measured with CD34 and CD105 antibodies, increased with increasing grades of astrocytoma. However, CD105 correlated more significantly with the increasing grades than CD34. Thus, CD105 is a superior endothelial marker than CD34 in the assessment of angiogenic activity of the astrocytic tumors.

The microvessel counts, when measured by CD34 are higher than that measured by CD105. This is because of the fact that CD34 measures pre-existing vessels that got integrated into the tumor whereas CD105 showed only proliferating vessels. There were very few studies reported in the literature regarding the significance of total vascular area as a morphometric parameter in the evaluation of angiogenic activity of different grades of tumor. Korkopoulou et al studied microvessel density, total vascular area (TVA) as well as several morphometric parameters related to vessel shape and size in astrocytic brain tumors. They found that although MVD, total vascular area and branching counts were adversely related to disease free survival in grades II and III in univariate analysis but in multivariate analysis, only total vascular area remained statistically significant. It showed that TVA and branching counts were prognostically more informative than MVD for patients with diffuse astrocytic tumors.<sup>[20]</sup>

In the present study, as we did not have any information regarding patients follow up, we could not determine the relationship between microvessel area and survival. But our study showed that there was statistically significant

difference in total microvessel area between all grades of astrocytoma ( $p$  value  $< 0.05$ ). It was suggested that microvessel area could be used as a measure of angiogenic activity in different grades of astrocytoma.

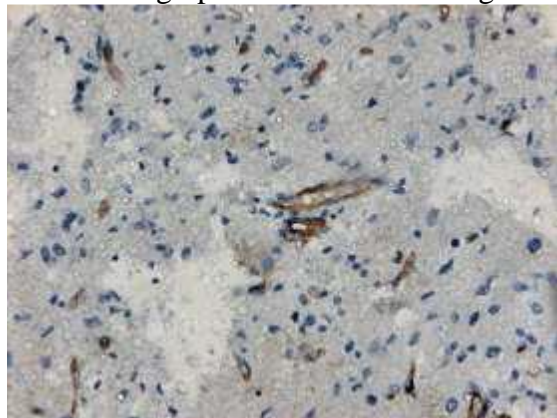
The present study performed on various grades of astrocytoma by using two different magnifications, do not show any significant difference in calculated microvessel density and total vascular area. This was an attempt to see any discrepancy in calculation when two different magnifications are used.

Tumor vessels provide a useful target for antineoplastic therapies. Anti-angiogenic therapy targeting CD105 can be a potential therapeutic tool for the malignant brain tumors.

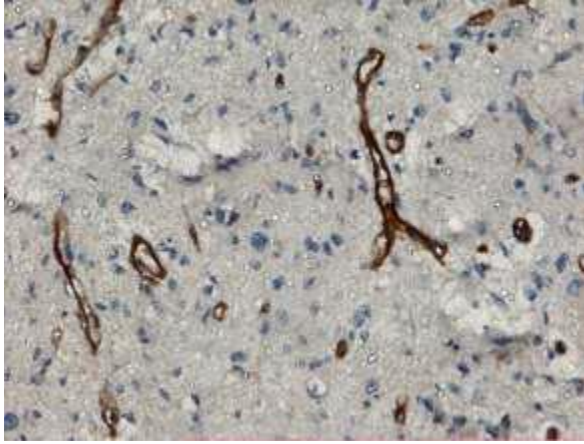
The present study concluded that astrocytic brain tumors exhibit potent angiogenic activity which increased significantly with increasing grades. Microvessel density and area determined by CD105 antibody was seen highly correlated with the increasing tumor grades. These finding further suggested the potential significance of characteristics of microvessel density and area as potential prognostic markers as well as their application in improved selection of patients for anti-angiogenic and other treatments. In the present era of newer anti-angiogenic therapies, astrocytic tumors' angiogenesis and alteration in vascular morphology definitely has prognostic significance and thus helps to improve the treatment modalities and patient care.

### **Photographs**

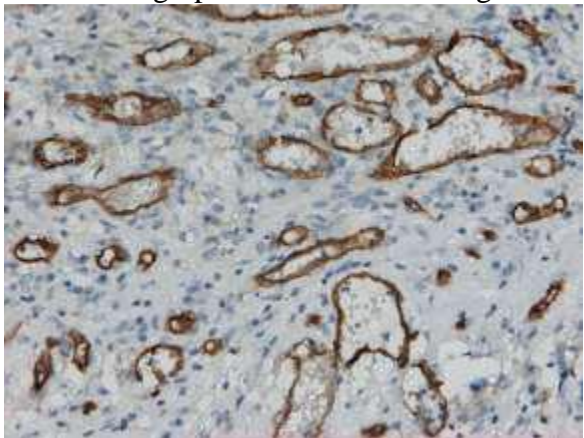
Photomicrograph 1: Microvessels in grade I astrocytoma (CD34; 200X)



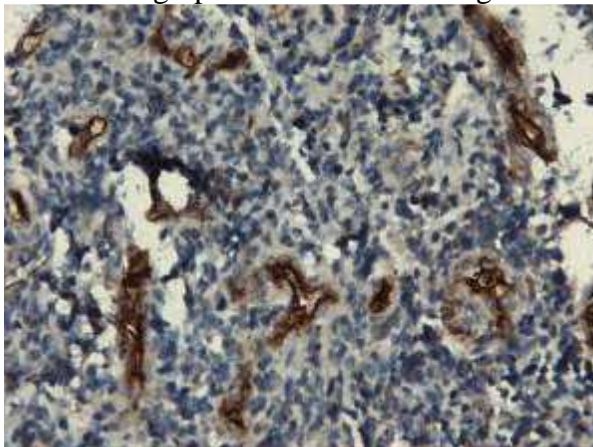
Photomicrograph 2: Microvessels in grade I astrocytoma (CD105; 200X)



Photomicrograph 3: Microvessels in grade IV astrocytoma (CD34; 200X)



Photomicrograph 4: Microvessels in grade IV astrocytoma (CD105; 200X)





## **REFERENCES**

1. Kleihues P, Cavenee WK. World health organization Classification of tumours – Pathology and Genetics. Tumors of nervous system. 2000 IARC Press, Lyon.
2. Beatriz M, Lopes S. Angiogenesis in Brain Tumors. *Microsc Res Tech* 2003;60:225-30.
3. Wesseling P, Ruiter DJ, Burger P. Angiogenesis in brain tumors; pathobiological and clinical aspects. *J Neurooncol* 1997;32(3):253-65.
4. Sugita Y. Angiogenesis of Primary brain tumors: The role of endoglin (CD105). In: Garami M (ed) *Molecular targets of CNS tumors*. In Tech, Croatia 2011 ; pp 127–140.
5. Duff SE, Li C, Garland JM, Kumar S. CD105 is important for angiogenesis: evidence and potential applications. *FASEB J* 2003;17:984 – 92.
6. Wang JM, Kumar S, Pye D, Haboubi N, al-Nakib L. Breast carcinoma: comparative study of tumour vasculature using two endothelial cell markers. *J Natl Cancer Inst* 1994; 86: 386–8
7. Yao D, Hongyang Z, Fangcheng Z, Jian C, Xiaobing J. Correlativity of Expression of Endoglin(CD105) with expressions of Vascular Endothelial Growth Factor and Ki-67 in Human Glioma. *Chin J Clin Neurosurg* 2006 ; 9 : 527-30.
8. Tanaka F, Otake Y, Yanagihara K, Kawano Y, Miyahara R, Li M, Yamada T, Hanaoka N. Evaluation of angiogenesis in non-small cell lung cancer: Comparison between anti-CD34 antibody and anti-CD105 antibody. *Clin Cancer Res* 2001; 7: 3410 – 3415.
9. Weidner N, Semple JP, Welch WR, Folkman J. Tumour angiogenesis and metastasis – correlation in invasive

breast carcinoma. *N Engl J Med* 1991; 324: 1 – 8.

10. Borre M, Offersen BV, Nerstrom B, Overgaard J. Microvessel density predicts survival in prostate cancer patients subjected to watchful waiting. *Br J Cancer* 1998;78: 940 – 944.

11. Giatromanolaki A, Sivridis E, Brekken R, Thorpe PE, Anastasiadis P, Gatter KC, et al. The angiogenic ‘vascular endothelial growth factor/flk-1/KDR receptor’ pathway in patients with endometrial carcinoma: Prognostic and therapeutic implications. *Cancer* 2001; 92: 2569–77.

12. Saclarides TJ, Speziale NJ, Drab E, Szeluga DJ, Rubin DB. Tumour angiogenesis and rectal carcinoma. *Dis Colon Rectum* 1994; 37: 921–6.

13. Laitakari J, Nayha V, Stenback F. Size, shape, structure and direction of angiogenesis in laryngeal tumor

development. *J Clin Pathol* 2004;57:394-401.

14. Netto GC, Bleil CB, Hilbig A, Coutinho L. Immunohistochemical evaluation of the microvessel density through the expression of TGF- $\beta$  (CD105/Endoglin) and CD34 receptors and expression of the vascular endothelial growth factor (VEGF) in oligodendrogliomas. *Neuropathology* 2008;28:7-23.

15. Kumar S, Ghellal A, Li C, Byrne G, Haboubi K, Wang J. Breast carcinoma: Vascular density determined using CD105 antibody correlates with tumor prognosis. *Cancer Res* 1999; 59:856-61.

16. Yao Y, Pan Y, Chen J, Sun X, Qiu Y, Ding Y. Endoglin (CD105) Expression in Angiogenesis of Primary Hepatocellular Carcinomas: Analysis using Tissue Microarrays and Comparisons with CD34 and VEGF. *Ann Clin Lab Sci* 2007;37(1):39-48.

17. Sugita Y, Takase Y, Mori D, Tokunaga O, Nakashima A, Shigemori M. Endoglin (CD 105) is expressed on endothelial cells in the primary central nervous system lymphomas and correlates with survival. *J Neurooncol* 2007;82:249–56.
18. Yao Y, Kubota T, Takeuchi H, Sato H. Prognostic significance of microvessel density determined by anti-CD105/Endoglin monoclonal antibody in astrocytic tumors: Comparison with an anti-CD31 monoclonal antibody. *Neuropathology* 2005 Sep; 25(3):201-6.
19. Behrem S, Zarkovic K, Eskinja N, Jonjic N. Endoglin is a better marker than CD31 in evaluation of angiogenesis in glioblastoma. *Croat Med J* 2005 Jun;46(3):417-22.
20. Korkolopoulou P, Patsouris E, Kavantzias N, Konstantinidou A, Christodoulou P, Tsagli TE, et al. Prognostic implications of microvessel morphometry in diffuse astrocytic neoplasms. *Neuropathol Appl Neurobiol* 2002 Feb;28(1):57-66.