

Case Report

Total transection of pancreatic head by blunt abdominal trauma

S. Buci¹, D. Shtjefn¹i, S. Koceku¹, E. Markeci, Gj. Bushi¹, S. Ruci¹

Surgery Service, University Hospital of trauma, Tirana, ALBANIA

Article Received 20-12-2020, Accepted 09-01-2021, Published 20-01-2021

Abstract

Introduction: Isolated pancreatic blunt trauma are rare and very difficult to be identified, occurring 0.2-6 % in all the cases of an abdominal blunt trauma. The key to optimal treatment is related to the total integrity of Wirsung duct.

Objective: The goal of this study is to accurately report the clinical management of the pancreatic trauma with Wirsung duct transection.

Material and methods: Introduction of a patient with blunt abdominal trauma, having a total transection of pancreatic head, no evident duodenal injuries.

Results: A 41 years old man, that was victim of an aggression with multiple punches and kicks in the abdominal area and lower extremities. Clinical inspection reveals ecchymosis on the epigastric area. The patient arrived at the hospital 4 hours after the aggression. He complained strong abdominal pain. The clinical findings reveals hemodynamic stability of the patient, high abdominal sensation, normal laboratory levels of lipase and amylase enzymes. CT scan detects transection of the pancreatic head (Class III Lucas), perihepatic free fluid and on omental bursa. Surgery has been performed 6 hours

after trauma. Surgical findings consisted in total transection of pancreatic head, Wirsung duct rupture and preserved integrity of duodenum and other abdominal organs. Surgical procedure consisted in Roux-Y pancreatico-jejunostomy, ligature of the distal part of the Wirsung duct of the head, proper hemostasis of the pancreatic head, peritoneal lavage and drainage. Postoperative prognosis was encouraging and no complications occurred. 10 days after surgery the patient is fully recovered and he was discharged.

Conclusion: The radiological modalities have a essential role in the evaluation of the injuries in a pancreatic trauma. Operative management is requested in severe injuries of pancreatic glandule. The prognosis of pancreatic trauma is related mainly of the injuries of pancreatic duct.

Introduction:

Pancreatic trauma is rare, it occurs in approximately 1-6% of patients with abdominal injuries [1-2].

Isolated pancreatic injuries occurs approximately in 1-12% of cases sustaining pancreatic injuries [3].

Car crash is the main cause of pancreatic injury in Europe and USA, gunshot wounds occurs in 30-45 % of cases [3].

In children, bicycle mishaps are also a common cause of abdominal injuries, especially when the abdomen is stuck by the handlebars [4-5].

Prognosis of pancreatic injury is associated with the involvement of the main pancreatic duct, that determined the mortality and the risk of complications. An untreated and delayed diagnosis of pancreatic duct disruption lead often to secondary complications which needs surgical repair. The early diagnosis and the adequate treatment of the pancreatic injury has an important role in the morbidity and the mortality of the patients and radiology in this case has a pivot role in the immediate and prompt diagnosis of the pancreatic injury [7-8].

The morbidity due to pancreatic injury is approximately 45 % [9,10,11,12,13].

In cases of delayed treatment , morbidity can be approximately 60% [14,15,16].

The mortality in isolated pancreatic injury varies from 2% to 17% [10].

The purpose of this case report is to report the management of a total rupture of the pancreatic head.

Case Presentation

A 41 years old man, victim of a human aggression presented to the emergency department of the University Hospital of Trauma in Tirana 4 hours after the aggression. Clinical findings reveals ecchymoses on the epigastric region, abdominal pain without peritoneal involvement, hemodynamic stability and normal laboratory findings. CT scan was

performed and revealed a total transection (class III according to Lucas classification) of the pancreatic head nearby the duodenum, free perihepatic fluid and in the omental bursa too.

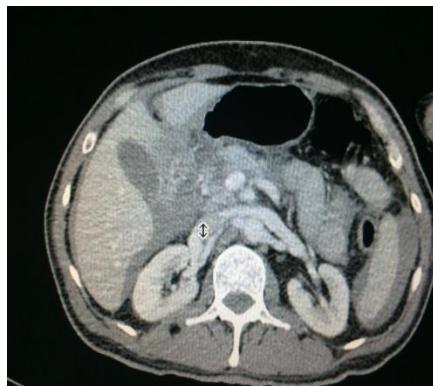

Figure 1. Gr.III transection of pancreatic head, free fluid in perihepatic space and in the omental bursa.

After six hours of clinical and radiologic evaluation, laparotomy has been performed.

Surgical Management

Patient underwent abdominal laparotomy with median superior incision elongated below the umbilicus. Surgical findings consisted in hemoperitoneum, total transection of pancreatic head nearby duodenum (thickness of pancreatic tissue remained was approximately 3-4 mm). The transection of pancreatic duct was easily identified with preserved integrity of pancreatic body and tail tissue , duodenum and other abdominal organs .

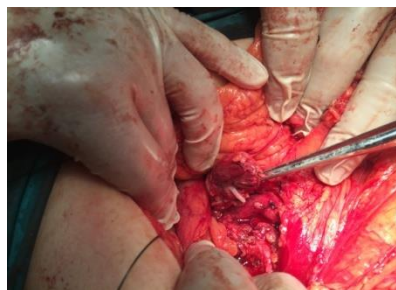

Figure 2. Transection of pancreatic duct, transection of pancreatic head.

The surgical procedure consisted in Roux-y pancreatico-jejunostomy, the pancreatic stump is invaginated into the jejunal loop according to Houdart E. The distal part of the pancreatic duct is closed by a ligature and it is performed a proper hemostasis of the remained pancreatic tissue nearby duodenal U. In the end, it is done peritoneal lavage and drainage. The 2 surgical drains are placed in omental bursa and Douglas pouch. The postoperative period was normal.

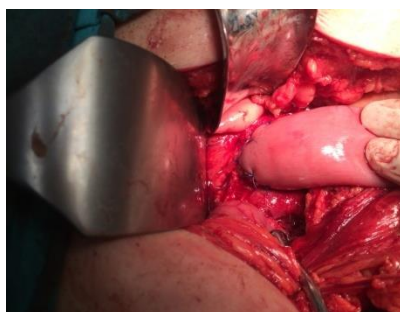

Figure 3. Roux-Y pancreatico-jejunostomy according to Houdart E.

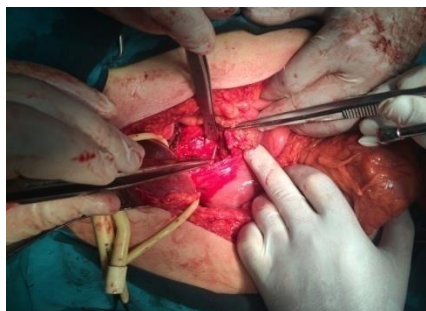


Figure 4. Distal Wirsung duct ligation. Proper hemostasis of the pancreatic head.

10 days after the surgery the patient is fully recovered and he was discharged.

Discussion

Pancreatic injuries are often characterized from a mis correlation between grade of injury and the onset symptoms. The delayed

diagnosis can lead to serious complications which are difficult to treat.

Even patients with total transection of pancreatic duct can be asymptomatic for months [17,18, 19].

Retroperitoneal location of this organ and delayed appearance of the clinical symptoms make difficult the diagnosis in pancreatic injuries.

CT scan is the examination of choice as a non-invasion procedure in hemodynamically stable patients with abdominal trauma. This examination has about 40% of sensibility in the first hours of trauma [6].

Accordingly, the overall sensitivity for CT in correctly predicting the existence of an unspecified pancreatic injury was 71.4%, but with a low prediction in duct injuries [6,20].

To our patient the CT scan examination revealed a total transaction of the pancreatic head (Lucas III), nearby duodenum, free perihepatic fluid and in the omental bursa.

Magnetic resonance cholangiopancreatography (MRCP) insures more significant images of the pancreatic duct and his injuries [21].

Endoscopic retrograde cholangio-pancreatography (ERCP) permit the realisation of a full mapping of the duct, with sensibility of 100% in detection of abnormalities [22].

It has to be performed as soon as possible, possibly in the first 12-24 hours after trauma [22,23].

Although, this technique includes the risk of infection of glandular tissue. MRCP has a sensibility of 87-100 % and a specificity of 81% [24], it can replace ERCP because of it's non-invasive .

Magnetic resonance pancreatography is being used with increasing frequency as an alternative to ERCP [25].

In the small pancreatic injuries is needed operative management but the disruption of the pancreatic duct needs operative management. The results depend on the age, concomitant injuries, the grade of injury and the response to the treatment [26,27,28].

Pancreatic injuries (Lucas I,II) consist of the major part of the pancreatic trauma.

The decision to undergo laparotomy can be difficult in isolated pancreatic injury, but in our case, we suspect a disruption of pancreatic duct.

Drainage with every local debridement requested is more frequently done [29,30].

Not every injury of the pancreatic capsule must to be repaired by sutures, because this lead to necrosis of pancreatic tissue [31].

Transection of the head of the pancreas (Lucas III) ,it can be conserved by realizing pancreatico-jejunostomy Roux-en-Y and suturing the distal part of the pancreatic head [32,33].

In our case, the remained pancreatic tissue (body, tail) resulted with a normal pancreatic view.

We realised pancreaticojejunostomy Roux-en-Y, with the invagination of the pancreatic stump into the jejuna loop according to Houdart E. The postoperative period was very good without complications. 10 days after the surgery the patient is fully recovered and discharged.

This is a good option when there is no doubt of the dysfunction of the remained pancreatic tissue, especially if the resection included more than 80% of the

gland[34,35]. The alternative is the distal pancreatectomia .

When the damage is at the level of isthmus or body (Lucas II), the major part of authors are fan of the distal pancreatic excision because the morbidity, the mortality and the hospitalisation of the patient are much lower than when it is done external drainage of the pancreatic injury. When external drainage is performed we might have complications such as abscess, distal pancreatitis, pseudocyst or pancreatic fistula [36].

Endoscopic transpapillary drainage of pancreas is technically possible in a disruption of the pancreatic duct (Lucas II, III), diagnosed by CPRM and /or CPRE. This technique has been very successfully in children and adults in the centres when it is applied [37,38].

Patients with a traumatic injury of the pancreas are sensible of immediate or delayed consequence of this process of diseases [20,39].

The injury of ductal system ,if it is not treated properly or not treated at all must have extended morbidity. The complications of a traumatic injury of the pancreas are huge in number, that vary from simple pancreatitis to death [40,41].

The mortality of pancreatic injuries is approximately 20% due to hemorrhage of the injury of the other intra-abdominal organs and sepsis [40,42].

Conclusion:

The radiological modalities have a essential role in the evaluation of the injuries in a pancreatic trauma.

Operative management is requested in severe injuries of pancreatic glandule.

The prognosis of pancreatic trauma is related mainly of the injuries of pancreatic duct.

References

1. Jacombs ASW, Wines M, Holland AJA, Ross FI, Shun A, Cass DT. Pancreatic trauma in children. *J. Pediatr. Surg.* 2004 janv;39(1):96-99.
2. Meier DE, Coln CD, Hicks BA, Guzzetta PC. Early operation in children with pancreas transection. *J. Pediatr. Surg.* 2001 févr;36(2):341-344.
3. Khan. T.F.T, Zahari. A. Diagnosis and management of blunt pancreatic trauma: A case report r with review of the literature. *Med J Malaysia*, Vol 48, N 2, June 1993.
4. Stringer MD. Pancreatic trauma in children. *Br J Surg* 2005 avr;92(4):467-470.
5. Jobst MA, Canty TG Sr, Lynch FP. Management of pancreatic injury in pediatric blunt abdominal trauma. *J. Pediatr. Surg.* 1999 mai;34(5):818-823; discussion 823-824.
6. Bradley EL 3rd, Young PR Jr, Chang MC, Allen JE, Baker CC, Meredith W, Reed L, Thomason M. Diagnosis and initial management of blunt pancreatic trauma: guidelines from a multiinstitutional review. *Ann. Surg.* 1998 juin;227(6):861-869.
7. Wong YC, Wang LJ, Lin BC, Chen CJ, Lim KE, Chen RJ. CT grading of blunt pancreatic injuries: prediction of ductal disruption and surgical correlation. *J Comput Assist Tomogr.* 1997;21:246-250.
8. Fischer JH, Carpenter KD, O'Keefe GE. CT diagnosis of an isolated blunt pancreatic

injury. *AJR Am J Roentgenol.* 1996;167:1152.

9. Patton JH, Jr, Lyden SP, Croce MA, Pritchard FE, Minard G, Kudsk KA, et al. Pancreatic trauma: A simplified management guideline. *J Trauma.* 1997;43:234-9.
10. Jurkovich G, Bulger EM. Duodenum and pancreas. In: Mattox KL, Moore ME, Feleciano DV, editors. *Trauma.* New York: McGraw-Hill Companies; 2004. pp. 709-34.
11. Wind P, Turet E, Cunningham C, Frileux P, Cugnenc PH, Parc R. Contribution of endoscopic retrograde pancreatography in management of complications following distal pancreatic trauma. *Am Surg.* 1999;65:777-83.
12. Lin BC, Chen RJ, Fang JF, Hsu YP, Kao YC, Kao JL. Management of blunt major pancreatic injury. *J Trauma.* 2004;56:774-8.
13. Wolf A, Bernhardt J, Patrzyk M, Heidecke CD. The value of endoscopic diagnosis and the treatment of pancreas injuries following blunt abdominal trauma. *Surg Endosc.* 2005;19:665-9.
14. Wind P, Turet E, Cunningham C, Frileux P, Cugnenc PH, Parc R. Contribution of endoscopic retrograde pancreatography in management of complications following distal pancreatic trauma. *Am Surg.* 1999;65:777-83.
15. Lin BC, Chen RJ, Fang JF, Hsu YP, Kao YC, Kao JL. Management of blunt major pancreatic injury. *J Trauma.* 2004;56:774-8.
16. Wolf A, Bernhardt J, Patrzyk M, Heidecke CD. The value of endoscopic diagnosis and the treatment of pancreas

injuries following blunt abdominal trauma. *Surg Endosc.* 2005;19:665–9.

17. Anderson, C.R., Connors, J.P., Meija, D.C., and Wise, L. Drainage methods in the treatment of pancreatic injuries. *Surg Gynecol Obstet.* 1974; 138: 587–590.

18. Berni, G.A., Bandyk, D.F., Oreskovich, M.R., and Carrico, C.J. Role of intraoperative pancreatography in patients with injury to the pancreas. *Am J Surg.* 1982; 143: 602–605.

19. Smego, D.R., Richardson, J.D., and Flint, L.M. Determinants of outcome in pancreatic trauma. *J Trauma.* 1985; 25: 771–776.

20. Akhrass, R., Kim, K., and Brandt, C. Computed tomography. An unreliable indicator of pancreatic trauma. *Am Surg.* 1996; 62: 647–651.

21. Gupta A, Stuhlfaut JW, Fleming KW, Lucey BC, Soto JA. Blunt trauma of the pancreas and biliary tract: a multimodality imaging approach to diagnosis. *Radiographics.* 2004;24:1381–1395.

22. Whittwell A. E., Gomez G. A., Byers P, Kreis D. J. Jr, Manten H, Casillas V. J.. Blunt pancreatic trauma: prospective evaluation of early endoscopic retrograde pancreatography. *South Med J.* 1989;82(5):586–91.

23. Bleichner J. P., Guillou Y. M., Martin L, Seguin P, Malledant Y. Pancreatitis after blunt injuries to the abdomen. *Ann Fr Anesth Reanim.* 1998;17(3):250–3.

24. Gomez M. A., Besson M., Scotto B, Roger R, Alison D. MR imaging in the evaluation of blunt pancreatic trauma. *J Radiol.* 2004;85(4 Pt 1):414-7.

25. Fulcher, A.S. and Turner, M.A. MR pancreatography: a useful tool for evaluating pancreatic disorders. *Radiographics.* 1999; 19: 5–24.

26. Chen Y, Jiang Y, Qian W, Yu Q, Dong Y, Zhu H, Liu F, Du Y, Wang D, Li Z. Endoscopic transpapillary drainage in disconnected pancreatic duct syndrome after acute pancreatitis and trauma: long-term outcomes in 31 patients. *BMC Gastroenterol.* 2019 Apr 16;19(1):54.

27. Pereira R, Vo T, Slater K. Extrahepatic bile duct injury in blunt trauma: A systematic review. *J Trauma Acute Care Surg.* 2019 May;86(5):896-901.

28. Gabriel V, Grigorian A, Nahmias J, Pejcinovska M, Smith M, Sun B, Won E, Bernal N, Barrios C, Schubl SD. Risk Factors for Post-Operative Sepsis and Septic Shock in Patients Undergoing Emergency Surgery. *Surg Infect (Larchmt).* 2019 Apr 05.

29. Vasquez JC, Coimbra R, Hoyt DB, Fortlage D. Management of penetrating pancreatic trauma: an 11-year experience of a level-1 trauma center. *Injury* 2001; 32: 753–759.

30. Young PR, Meredith JW, Baker CC et al. Pancreatic injuries resulting from penetrating trauma: a multi-institution review. *Am Surg* 1998; 64: 838–843.

31. Fabian TC, Kudsk KA, Croce MA et al. Superiority of closed suction drainage for pancreatic trauma. *Ann Surg* 1990; 211: 724–728.

32. Andersen DK, Bolman RM, Moylan JA. Management of penetrating pancreatic injuries: subtotal pancreatectomy using the Auto Suture stapler. *J Trauma* 1980; 20: 347–349.

33. Degiannis E, Levy RD, Potokr Tet al. Distal pancreatectomy for gunshot injuries of the distal pancreas. *Br J Surg* 1995; 82: 1,240–1,242.
34. Jurkovich, G.J. and Carrico, C.J. Pancreatic trauma. *Surg Clin North Am.* 1990; 70: 575–593.
35. Leppaniemi, A.K. and Haapiainen, R.K. Pancreatic trauma with proximal duct injury. *Ann Chir Gynaecol.* 1994; 83: 191–195.
36. Zerbib P., Brams A., Chambon J.P. Les fractures ishmiques du pancréas *Ann Chir* 2001; 126 : 421-426.
37. Kim H. S., Lee D. K., Kim I. W., Baik S. K., Kwon S. O., Park J. W., Cho N. C., Rhoe B. S.. The role of endoscopic retrograde pancreatography in the treatment of traumatic pancreatic duct injury. *Gastrointest Endosc.* 2001;54(1):49–55.
38. Telford J. J, Farrell J. J., Saltzman J. R., Shields S. J., Banks P. A., Lichtenstein D. R., Johannes R. S., Kelsey P. B., Carr-Locke D. L.. Pancreatic stent placement for duct disruption. *Gastrointest Endosc.* 2002;56(1):18–24.
39. Debi U, Kaur R, Prasad KK, Sinha SK, Sinha A, Singh K. Pancreatic trauma: a concise review. *World J Gastroenterol.* 2013 Dec 21;19(47):9003–11.
40. Heitsch RC, Knutson CO, Fulton RL, Jones CE. Delineation of critical factors in the treatment of pancreatic trauma. *Surgery.* 1976;80:523–529.
41. Campbell R, Kennedy T. The management of pancreatic and pancreaticoduodenal injuries. *Br J Surg.* 1980;67:845–850.
42. Jones RC. Management of pancreatic trauma. *Ann Surg.* 1978;187:555–564.