

Malignant otitis externa, a virulent disease of diabetic middle aged and elderly. Benghazi Medical Center experience.

Authors:

Weeam Nagi Mahmoud Mustafa¹, Agila Albarasi¹, Rema A. Howaij², Waeil I.T. Kawafi^{3*}

¹Division of Otolaryngology, Department of Surgery, Benghazi Faculty of Medicine, University of Benghazi, Libya

²Department of Internal Medicine, El-Marj Faculty of Medicine, University of Benghazi, Libya

³Department of Family & Community Medicine, El-Marj Faculty of Medicine, Libya

*Correspondent Author:

Waeil I.T. Kawafi, Department of Family & Community Medicine, El-Marj Faculty of Medicine, Libya

Article Received: 01- October -2024, Revised: 21-October-2024, Accepted: 11-November-2024

ABSTRACT:

Malignant otitis externa is an infectious condition mainly in diabetic elderly, affects the primarily external auditory canal, and may extend causing lethal consequences. This cases series study attempts to describe characteristics, management and outcome of cases with this condition in otorhinolaryngology department in Benghazi medical center during eight years' experience from 2011 to 2019. The study included 41 patients with this diagnosis all were diabetic middle aged or elderly, none had strict control of his diabetes. Otagia and external canal edema manifested in all cases. External auditory canal thickening, granulation tissue, bone erosion and destruction were prominent imaging features. All cases obtained management by using; aural toilet, ear wick, local antibiotics and parenteral antibiotics with only small proportion received chemotherapy. Residual seventh nerve palsy was evident among 14.63 %; with no statistically significant difference from admission figure ($P > 0.05$). Recurrence was reported among 21.95% of the series; with no statistically significant differences across different factors. Erythrocyte sedimentation rate had statistically significant association with recovery. Hospital stay averaged 15.3 days which is comparable with other hospitals abroad. Control of diabetes and early response to otalgia and hearing difficulty may be helpful in better outcomes. The local management policy appears satisfactory but further research may be needed.

Keyword: Malignant otitis externa, diabetic, Benghazi Medical Center, outcomes.

INTRODUCTION:

Malignant otitis externa (MOE) is an infectious condition that mainly caused by *Pseudomonas aeruginosa* and affects the external auditory canal, temporal bone and base of the skull. It is a virulent and lethal inflammatory disease usually begins as an external otitis that progress into an osteomyelitis of the temporal bone. Spread of the disease outside the external auditory canal occurs through the fissures of Santorini and the osseo-cartilaginous junction. ^{1 - 3}. The public health importance of MOE presents as an emerging disease with recently increasing incidence and progressive debilitating condition among elderly poorly controlled diabetic patients with high case fatality. ^{4, 5}

The mechanism of increased susceptibility of diabetics for getting MOE is the formation of diabetic microangiopathy and white cell function impairment. ^{6,7}

The increase in incidence may relate to improvement in awareness levels about the disease and availability of

advanced diagnostic modalities. ⁴ Anyhow, this trend was noticeable in developing countries as India as well as western states like UK. ^{4, 8}. Despite the decline in mortality figures related to MOE during the last two decades, it is still recognized as a fatal clinical condition with case fatality rate ranging from 20 to 60%, particularly; in developing countries. Patients with cranial neuropathies (other than VII), intracranial complications, or with irreversible systemic immunosuppression are typical victims. ⁹⁻¹¹

Aim of the Study:

- 1- To describe the personal and clinical characteristics of MOE cases.
- 2- To illustrate the radiological findings and management of MOE cases.
- 3- To estimate the outcome of MOE cases.

PATIENTS AND METHODS:

A case series (descriptive) study involving the medical records of malignant otitis externa cases admitted to otorhinolaryngology department in Benghazi medical center during the period (1st August 2011- 31st August 2019) were reviewed retrospectively.

Exclusion Criteria:

Malignant otitis externa cases aged less than 18 years were excluded from the study.

A record sheet was used to collect the required data. This record sheet included three parts:

Part I- included demographic data such as; gender, age of patients, medical history of diabetes mellitus, renal failure, and any disturbance in immunological status. In addition to use of certain medications as; steroids, chemotherapy, radiotherapy. Part II- the data related to clinical features and laboratory results. Part III- the data related to complications of malignant otitis externa, which may include cranial nerve palsies and basal skull osteomyelitis.

The following considerations were taken carefully during conduction of the study. Confidentiality and privacy of the data were maintained. The approval of BMC manager and head of ENT department were taken before conduction of the study-

The collected data, after checking their completeness entered into Statistical Package of Social Sciences

(SPSS) version 22 for analysis. Descriptive statistics of participants' characteristics, using proportions in the form of tables and graphical presentation were used. Additionally, measures of central tendency such as mean, median, mode and standard deviation (SD) were applied.

RESULTS:

During the study period, 41 malignant otitis externa cases were admitted to otorhinolaryngology department in Benghazi medical center.

CASE CHARACTERISTICS:

Malignant otitis externa case aged between 48 and 90 years. The median age was 63 years. Mean \pm SD = 65.17 \pm 9.46 years. Female cases of malignant otitis externa represented a higher proportion (25/41; 60.98 %) compared to 16/ 41; 39.02% for males. All malignant otitis externa cases had history of chronic disease. Furthermore, all of them had history of diabetes mellitus with duration of mean \pm SD = 12.10 \pm 8.47 years and ranged between 2 and 40 years. Alternatively, none of these cases gave history of any of the immunological diseases. Clinical manifestations are shown in figure (1). 7.32 % of malignant otitis externa cases had history of medication with steroids. Only 2.44 % of malignant otitis externa cases gave history of medication with chemotherapy.

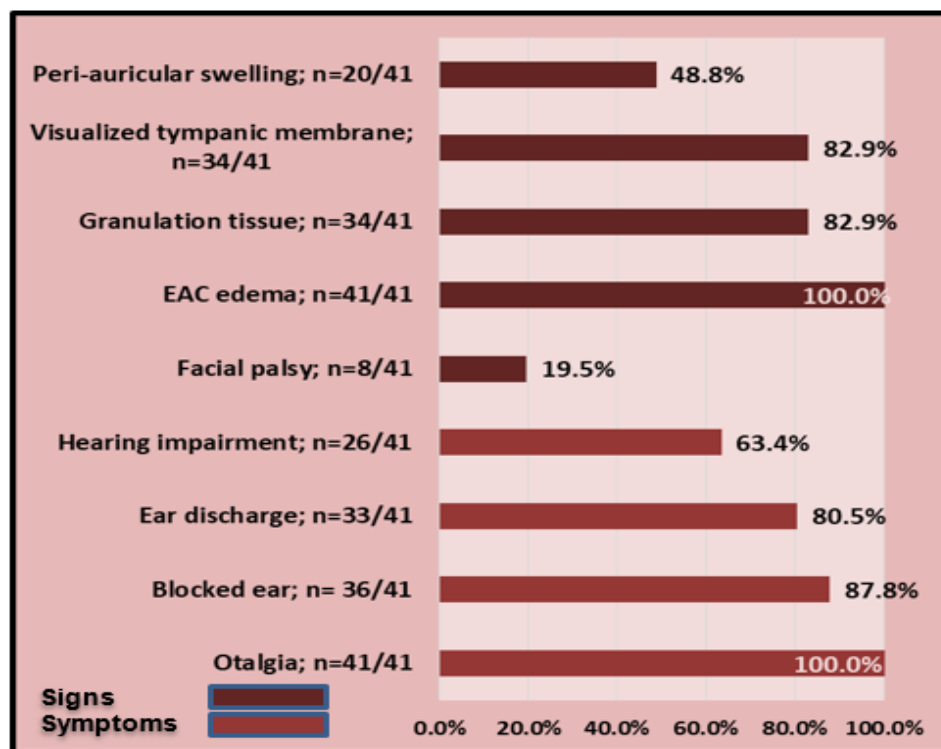


Figure (1): Rates of clinical manifestations among malignant otitis externa cases, BMC (2011- 2019). EAC External auditory canal

RADIOLOGICAL FINDINGS OF MALIGNANT OTITIS EXTERNA CASES:

The common features detected among the case series included edema; seen in 87.8% of cases, granulation tissue (GT); seen in 85.3%, thickening of external auditory canal (EAC); seen in 24.3% of the cases, and bone erosion or destruction (BE /BD) which was seen in 12.1% of the series. See figure 2

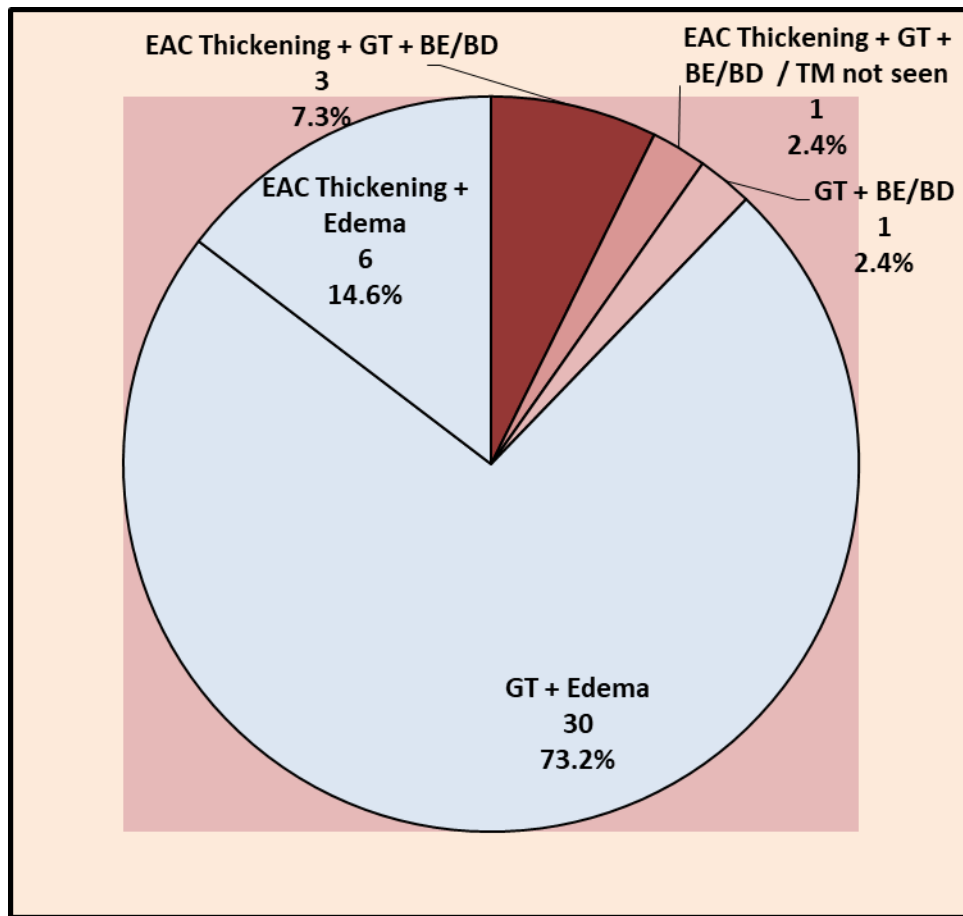


Figure (2): Distribution of malignant otitis externa cases according to computerized scanning findings, BMC (2011-2019)

EAC External auditory canal GT Granulation tissue BE Bone erosion BD Bone destruction TM Tympanic membrane

MANAGEMENT AND OUTCOME OF CASES:

All malignant otitis externa cases obtained management by using; aural toilet, EAC wick, local antibiotics and IV antibiotics. Most of cases (29/41; 70.7%) had also cauterization with silver nitrate. Residual seventh nerve palsy was evident among 6/41 cases (14.63 %); with no significant difference from admission figure ($P > 0.05$). Recurrence was reported among 21.95% of the series. Duration of improvement of MOE cases in days ranged 2 to 10 days (Mean \pm SD: 4.59 \pm 2.04 days). While

length of hospital stay of MOE cases in days ranged 8 to 27 days (Mean \pm SD: 15.28 \pm 5.44 days). The length of hospital stay was longer for cases with reported recurrence. The difference was statistically significant. While, age of patients, duration of diabetes mellitus (years), level of HAlc% and presence of granulation tissue were homogeneous across the status of recurrence. See table (1)

Table (1): Patient parameters according to recurrence status

Manifestation	Recurrence cases	Non recurrence cases	<i>P</i>
Age of patients Mean (\pm SD)	66.11 (\pm 10.85)	64.91 (\pm 9.21)	> 0.05
Duration of diabetes mellitus (years) Mean (\pm SD)	13.44 (\pm 10.18)	11.72 (\pm 8.07)	> 0.05
Level of HA1c% Mean (\pm SD)	9.022 (\pm 1.36)	8.95 (\pm 0.99)	> 0.05
Presence of granulation tissue N (%)	7 (77.8%)	27 (84.4%)	> 0.05
Length of hospital stay in days Mean (\pm SD)	18.44 (\pm 3.50)	14.35 (\pm 5.60)	0.046*

SD standard deviation, HA1c % the proportion of glycated hemoglobin.

Erythrocyte sedimentation rate (ESR) of MOE cases (in mL per hour) demonstrates observable drop at discharge. The difference was statistically significant ($P < 0.001$). While, hemoglobin level, white blood cell count, blood urea levels and serum creatinine levels did not show statistically significant difference. See table (2).

Table (2): Patient blood markers comparison on admission and discharge

Marker	On admission	On discharge	<i>P</i>
Hemoglobin level (gm/dL) Mean (\pm SD)	12.56 (\pm 1.29)	11.87 (\pm 1.17)	> 0.05
White blood cell count (thousands /dL) Mean (\pm SD)	8.83 (\pm 2.15)	6.26 (\pm 1.35)	> 0.05
ESR (per hour) Mean (\pm SD)	69.80 (\pm 23.04)	29.19 (\pm 9.05)	<0.001*
Urea levels (mg/dL) Mean (\pm SD)	25.90 (\pm 10.01)	23.29 (\pm 5.60)	> 0.05
Creatinine levels (mg/dL) Mean (\pm SD)	1.09 (\pm 1.65)	0.70 (\pm 0.38)	> 0.05

SD standard deviation, mg milligram, dL deciliter, ESR erythrocyte sedimentation rate

DISCUSSION:

PERSONAL CHARACTERISTICS:

This study showed that the mean age of MOE cases was 63 years. Sardesai RB et al (2002) ¹² studied six cases of MOE admitted to an Indian hospital during a period of 10 years from 1989-1999 their average age of 58 years. AbdulAziz A and Yasser AM (2003) ¹³ they studied nine MOE patients admitted to one of the Saudi teaching hospitals over a period of 6 years (1997-2003). All nine patients were male, their age ranged from 51-72 year (mean 61.5). On the contrary, our study shows that

females represented a higher proportion (60.98 %) compared to 39.02% of male cases.

All of the studied cases of MOE were diabetic. Correspondingly, Soheilipour S et al (2013) ¹⁴, all the studied MOE patients admitted to the Department of Otolaryngology, Head and Neck Surgery Section, Al-Zahra hospital in Isfahan province, Iran were diabetic. While as published by Chin R et al (2012) ¹⁵, MOE patients admitted to an Australian tertiary referral institution, only thirteen of the twenty-four patients (54%) were diabetic.

None of the studied cases included in the present study gave history of any of the immunological diseases. Nevertheless, 7.32 % and 2.44 % of the studied MOE cases received steroids and chemotherapy respectively. These medications could be associated with immunosuppression. Soheilipour S et al (2013) ¹⁴ reported that one of the predisposing factors was immunosuppression due to kidney transplantation in one of MOE cases. Similarly, Chin R et al (2012) ¹⁵ illustrated that three of the studied patients have been immunosuppressed.

Marina S et al (2019) ¹⁶ demonstrated that elderly individuals with DM are at risk of getting MOE. The risk of developing MOE among diabetics is more due to endarteritis, microangiopathy and small vessel obliteration. Additionally, in accordance to Geerlings SE and Hoepelman AI (1999) ¹⁷, DM reduces the chemotactic and bactericidal activity of human leukocytes. Subsequently, both the immune and granulocyte function becomes poor.

CLINICAL FEATURES OF CASES:

The clinical presentations of the studied cases were; otalgia, prevalent among all MOE cases, blocked ear (87.80%), ear discharge prevalent in 80 % of cases, decreased hearing (63.41%). In agreement with the present study Galletti B et al (2014) ¹⁸ reviewed 11 cases treated for MEO at the University Hospital, Italy (2003 – 2013) they found out that all patients presented with unilateral otalgia, 72.7% with otorrhoea.

The present study identified that 48.78 % had per auricular swelling and 20 % of MOE cases had facial palsy. In accordance with these findings, Galletti B et al (2014) ¹⁸ reported that 36.4% of their studied cases had cranial nerve lesion (27.3%; facial nerve palsy, and 9.1%; XI-XII nerves palsy), 27.3% complained of temporo-mandibular joint (TMJ) symptom, 27.3% with mastoid region swelling, 9.1% with fever and 9.1% with intraparotid lymphadenitis.

Microscopic examination revealed that all the studied MOE cases had edematous external canal and 82.9 % had granulation tissue on the external meatus. Galletti B et al (2014) ¹⁸ discovered similar findings in their study group as presence of granulation tissue in all cases, stenosis of external auditory canal in 72.7% of patients, and polyp in 27.3%. The present study showed that 17.50% of the studied MOE tympanic membrane could not be visualized.

RADIOLOGICAL FINDINGS OF CASES:

Regarding CT findings of the studied MOE cases, 73.17% had edematous canal with granulation tissue, followed by 14.6% of cases had edema of EAC with thickness, 7.3% of cases had diffuse thickening of EAC with granulation tissue and destruction of mastoid bone. Galletti B et al (2014) ¹⁸ reported that CT scan showed presence of soft tissue in the EAC in all cases. Other CT findings of the present study were; equal proportions of cases (2.4%) had thickening of EAC, granulation tissue, with bone destruction.

Galletti B et al (2014) ¹⁸ identified in their study that: 81.8% of cases had an erosion of the walls of the EAC, mastoid involvement was observed among 45.5% of cases, middle ear involvement in 45.5% of patients, TMJ involvement in 27.7% cases, skull base involvement in 18.2% of patients.

MANAGEMENT AND OUTCOME OF CASES:

The present study showed that white blood cells (WBC) was within normal range. Similarly, Alshaikh K et al (2019) ¹⁹ demonstrated that there was no leukocytosis in the studied MOE cases.

The studied cases of MOE had high level of the mean ESR of MOE on admission as compared to its level on discharge (69.80 mm / hour and 29.19 mm / hour) respectively. This drop in ESR level was achieved after proper management of the studied cases. A retrospective case review observational study from January 2013-December 2017 conducted by Marina S et al (2019) ¹⁶ in a tertiary referral center in India showed that ESR was more than 20 mm/hour in all the studied fourteen patients. After three weeks, ESR of six patients was repeated; their ESR had come to normal. Arsovic N et al (2020) ²⁰ and Byun YJ (2020) ²¹ showed that many of MOE cases had raised levels of ESR. According to Kaya I et al (2018) ², longstanding antibiotic therapy may be a necessity to treat MOE and decline in ESR is a good indicator for treatment response. They also added that uncontrolled diabetes mellitus and older age correlate to prolonged length of hospital stay. Level of HbA1C was high in the studied MOE cases, mean \pm SD of HbA1C on admission was 8.68 ± 1.08 mg /dl indicating a poor diabetes control profile among the series. This is in accordance with the results obtained by Kaya I et al (2018) ² as the mean HbA1c level at first laboratory investigation was more than 6mg/dl. In addition, Arsovic N et al (2020) ²⁰ reported that 46%, of MOE cases included in their study had elevated blood glucose level with the mean glycemic value of 10.1 mmol/L

All of the studied MOE cases were managed by using; aural toilet, EAC wick, local antibiotics and IV antibiotics. In agreement with this line of treatment, Carfrae MJ et al (2008)²² applied similarly aural toilet, local and IV antibiotics. Similarly, Hopkins ME et al (2018)²³ reviewed a cohort of patients diagnosed with MOE during 2006-2015 at the Royal Gwent Hospital in South Wales. The investigators demonstrated that aural toilet was applied in 97 % of MOE cases. Carfrae MJ et al (2008)²² and Hopkins ME et al (2018)²³ used similar management by using EAC wick antibiotics locally in addition to IV route.

The studied MOE cases had the mean length of stay of 15.28 days. Similar results were reported by a study conducted by Sharma S et al (2017)²⁴ revealed that the mean length of stay was significantly declined after introducing the management protocol was introduced (25.6 vs. 14.2 days).

The only reported complication among the studied MOE cases was the residual seventh nerve palsy, which was prevalent among 14.63 % of the cases. Arsovic N et al (2020)²⁰ demonstrated in their study similar results as facial nerve involvement (palsy or paresis) was proved in 15.5% of their studied patients and only one patient how had recovered the nerve function. This figure is still lower than 20% described by Franco-Vidal V et al (2007)²⁵.

In severe cases of MOE recurrence of infection after recovery could occur. The present study identified 21.95 % of MOE cases with history of recurrence. In concordance to this result, Omran AA et al (2012)²⁶ studied ten MOE patients; they attended the ENT department in Alexandria University, these cases had recurrence of infection over a period extended up to six months after-cure. In conclusion, MOE is a virulent disease mainly of elderly and diabetics that imposes aggressive longstanding management and surgical intervention along with close monitoring and strict control of diabetes. Case finding with optimal referral, diagnosis and management with good follow-up of MOE case is a multidisciplinary job of otolaryngology, diabetology and family practice staff.

CONCLUSION:

Recurrence was reported among 21.95% of the series; with no statistically significant differences across different factors. Erythrocyte sedimentation rate had statistically significant association with recovery. Hospital stay averaged 15.3 days, which appears comparable with other hospitals abroad. Control of diabetes and early response to otalgia and hearing

difficulty may be helpful in better outcomes. The local management policy appears satisfactory but further research may be needed.

REFERENCES:

- 1-Karaman E, Yilmaz M, Ibrahimov M, Hacıyev Y, Enve Malignant otitis externa. J Craniofac Surg. 2012 Nov. 23(6):1748-51r O.
- 2- Kaya İ, Sezgin B, Eraslan S, Öztürk K, Göde S, Bilgen C, Kirazlı T. Malignant Otitis Externa: A Retrospective Analysis and Treatment Outcomes. Turk Arch Otorhinolaryngol 2018; 56(2): 106-10
- 3- AlEnazi AS, Al Sharhan SS, Telmesani LM, AljazanNA, Al Qahtani BM, Lotfy MA. The Impact of using the term “Diabetic Ear” for the patients with Skull Base Osteomyelitis. J Family Community Med. 2019; 26(1): 23–29
- 4- Restuti D R. Comprehensive management of malignant otitis externa with tuberculosis and cranial nerve paresis in geriatrics. ORLI. 2020; 50 (1): 77-83
- 5- Adegbiyi WA, Aremu SK., Olatoke F, Olajuyin AO, Olubunmu OK. Epidemiology of otitis Externa In Developing Country. Int J Recent Sci Res. 2017; 8(6): 18023-18027
- 6- Rajagopalan S. Serious infections in elderly patients with diabetes mellitus. Clin Infect Dis. 2005; 40(7): 990-6
- 7- Pérez P, Ferrer M J, Bermell A, Ramírez R, Saiz V, Gisbert J. Malignant otitis externa. Our experience. Acta Otorrinolaringol Esp. 2010;61(6):437–440
- 8- Sharma S, Corrah T, Singh A. Management of Necrotizing Otitis Externa: Our Experience with Forty-Three Patients. J Int Adv Otol 2017; 13: 394-8.
- 9- Lasisi AO, Nwaorgu OGB. Behavioural pattern of malignant otitis externa: 10-year review in Ibadan. Afr. J. Med. Med. Sci. 2001; 30:221-223.
- 10- Lee JE, Song JJ, Oh SH, Chang SO, Kim CH, Lee JH. Prognostic value of extension patterns on follow-up

magnetic resonance imaging in patients with necrotizing otitis externa. *Arch. Otolaryngol. Head Neck Surg.* 2011; 137:688-693.

11- Loh S, Loh WSMalignant otitis externa: an Asian perspective on treatment outcomes and prognostic factors. *Otolaryngol. Head Neck Surg.* 2013; 148:991-996.

12- Sardesai R B, Krishnakumar T. Malignant otitis externa-our experience. *Indian Journal of Otolaryngology and Head and Neck Surgery.*2002; 54 (2): 132-5

13-AbdulAziz A and Yasser AM. Management of Malignant Otitis Externa Bahrain Medical Bulletin.2003; 25(4): 1-7

14- SoheilipourS, Meidani M, Derakhshandi H,Emadifar M.Necrotizing external otitis: a case series. *B-ENT.*2013; 9: 61-6

15- Chin R, Roche P, Sigston E, Valance N. Malignant otitis externa: An Australian case series. *The surgeon.*2012; 10: 273 – 277

16- Marina S, Gautham MK, Rajeshwary A, Vadisha B, Devika TA. Retrospective review of 14 cases of malignant otitis externa, *Journal of Otology.* 2019. Available from: <https://doi.org/10.1016/j.joto.2019.01.003>. Accessed in: 3 /2/2020.

17-Geerlings SE and Hoepelman AI. Immune dysfunction in patients with diabetes mellitus (DM).*FEMS Immunol Med Microbiol.* 1999;26:259 - 65

18- Galletti B, Mannella VK, Santoro R, Cammaroto G, Freni F, Galletti F, et al. Malignant external otitis. A case series from an Italian tertiary-care hospital. *Acta Med. Mediterr.,* 2014, 30: 1317 – 23

19- Alshaikh K, Alqurashi A, Alenzi S, Alqahtan A,Alshaikh A. Clinical Review of Necrotizing Otitis Externa, a single center experience. *Saudi Journal of*

*Oto-Rhino-Laryngology Head and Neck Surgery.*2019; 21(1):13-8

20- Arsovic N, Radivojevic N, Jesic S, Babac S, Cvorovic L, Dudvarski Z. *J Int Adv Otol Malignant Otitis Externa: Causes for Various Treatment Responses* 2020; 16(1): 98-103

21- Byun YJ, Patel J, Nguyen SH, Lambert PR. Hyperbaric oxygen therapy in malignant otitis externa: A systematic review of the literature, *World Journal of Otorhinolaryngology-Head and Neck Surgery.* 2020; 7(4): 296 – 302

22- Carfrae MJ, Kesser BW,Malignant Otitis Externa, *Otolaryngologic Clinics of North America.* 2008; 41(3): 537-549

23- Hopkins M E, Harris A S, CuddihyP. Malignant otitis externa: patient demographics and outcome. *B-ENT.* 2018; 14: 53-58

24- Sharma S, Corrah T, Singh A. Management of Necrotizing Otitis Externa: Our Experience with Forty-Three Patients. *J IntAdv Otol* 2017; 13: 394-8

25- Franco-Vidal V, Blanchet H, Bebear C, Dutrone H, Darrouzet V. Necrotizing external otitis: a report of 46 cases. *OtolNeurotol* 2007; 28: 771-3.

26- Omran, A.A., El Garem, H.F. & Al Alem, R.K. Recurrent malignant otitis externa: management and outcome. *Eur Arch Otorhinolaryngol.* 2012; 269: 807–811